

# CHARLOTTE PERIO

Periodontics ♦ Implantology

# Perio News

... this newsletter represents our opinion about current periodontal technologies / procedures...

## Immediate Implants

### Background

In the previous newsletter, **Dental Implants**, we reviewed why implants are an excellent choice for tooth/teeth replacement. Given rapid advances in dental implant technology, the timing of dental implant placement has changed significantly. In the common clinical occurrence of the hopeless tooth needing extraction and replacement with a dental implant, the extraction socket was allowed time to heal and fill in with new bone prior to implant placement. This delayed approach often required up to 6 months before the extraction site was amenable to proper implant placement and positioning. Additionally, the extraction site would go through significant bone remodeling and resorption, frequently necessitating bone graft procedures at the time of implant placement or as a separate surgical procedure (thereby delaying treatment even further).

Today, in certain clinical scenarios we are able to place implants in an ideal position at the time of tooth extraction, thereby reducing surgical encounters and total treatment time.

This newsletter will review the important critical criteria for and benefits of immediate implant placement at the time of tooth extraction.

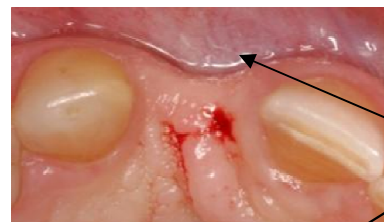
### Extraction healing

In the typical wound healing model, hard and soft tissue changes normally occur following tooth extraction. Bone resorption occurs, most notably in a horizontal dimension, especially during the first 3-6 months. Studies have demonstrated bucco-lingual bone resorption ranging from 3-7mm, a substantial loss of vol-

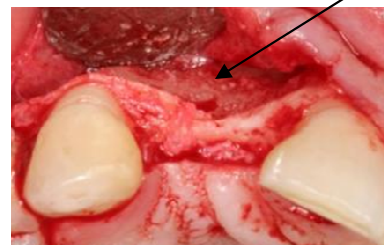
ume. Vertical bone loss occurs over a longer period of time and ranges from 2-4.5mm. The extent of bone resorption and resulting ridge defect depends on many factors, including:

- Thickness of the buccal wall of socket bone
- Resulting bone loss from a periodontal and/or periapical infection
- Previous acute traumatic event
- Long term trauma from occlusion
- Surgical trauma from extraction technique

Soft tissue changes follow the remodeling of the bone including the development of a buccal concavity and crestal "saddle" defect. Although the mesial and distal bone of the adjacent teeth may remain unchanged, the proximal papillae will flatten out unless supported by the transitional and/or final tooth replacement.



Facial soft tissue and bone cavity



Bone grafting and regenerative membranes are often utilized to minimize these hard and soft tissue changes, thereby preserving the ridge site for future implant placement.

## **Immediate implants: impact on bone and soft tissues?**

Recent research demonstrates that immediate implants can minimize detrimental bone and soft tissue changes that occur naturally after an extraction.

The presence of the implant can minimize the resorption of bone and can maintain critical soft tissue papillae height via the use of healing abutments and provisional crowns. This prevents facial plate resorption leading to gingival asymmetry as well as loss of papillae height resulting in open gingival embrasures or “black triangles”.

### **Extraction site / Implant Factors**

Extraction socket morphology is important as it affects the amount of implant-to-bone contact which affects initial stability of the immediate implant. The extraction site can influence the placement location which affects implant restorability.

If primary stability and ideal restorability can't be achieved, then placing the implant in a delayed manner is necessary.

Immediate implant stability and restorability are affected by:

- Adequate bone volume for ideal restorative provisionalization
- Bone surface area engaged by implant
- Bone beyond the apex of the tooth
- Maxillary sinus proximity
- Endodontic infection-periapical radiolucency
- Bone density and quality

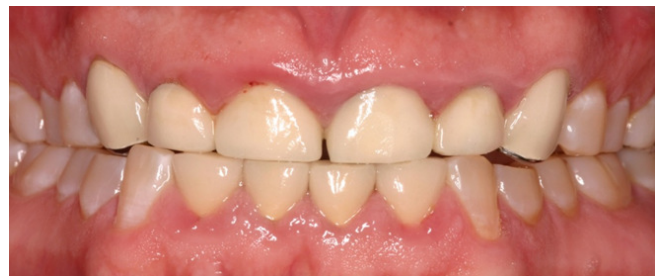## **Biotype**

Biotype has been described in many ways. From a periodontal perspective, the following criteria significantly affect bone and soft tissue dimensional changes after extraction:

- **Biotype:** Thick and thin
- **Papilla morphology:** Flat, scalloped, and highly scalloped

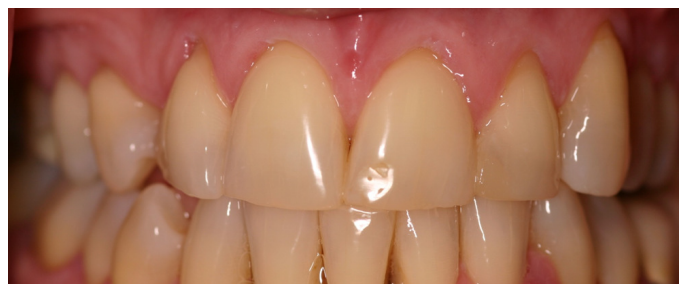### **Thick Biotype / Flat papilla:**

- Resilient to recession and papilla loss after extraction due to thick bone.
- Removable provisionalization and immediate temporization options for tooth replacement.
- Socket grafting may not be needed to maintain bone and soft tissue dimensions.



### **Thin Biotype / Scalloped Papilla:**

- More susceptible to recession and papilla loss after extraction due to thin bone.
- Removable provisionalization possible, but ideal contours critical to support the papilla and an ovate intaglio surface to shape the soft tissue.
- Immediate provisional crown or a customized healing abutment is ideal.
- Socket grafting and often soft tissue grafting needed to maintain bone and soft tissue dimensions.



## **Determining Ideal and Adequate Sites for Immediate Placement:**

When evaluating a site for an immediate implant, the following questions provide a simple to use formula for not only successful osseointegration of the implant but predictable hard and soft tissue stability over time (for a highly esthetic outcome).

The ***International Team for Implantology***\* created an assessment tool regarding esthetic risk factors. An accurate assessment will identify esthetic risk factors that impact the predictability of a highly esthetic outcome.

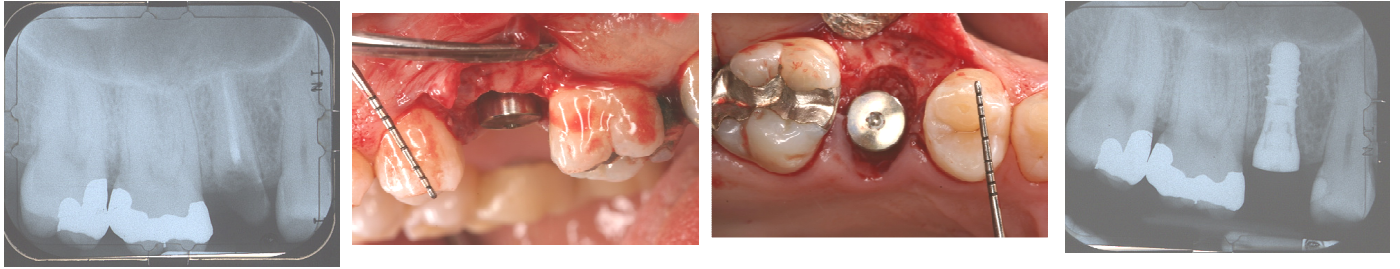
This helps determine when immediate versus delayed implant placement is indicated. It also aids in planning for bone and/or soft tissue grafting to overcome deficiencies at the proposed implant site.

<b>Esthetic Risk Factors</b>	<b>Low</b>	<b>Medium</b>	<b>High</b>
Medical Status	Healthy		Compromised
Smoking Habit	Non	< 10 per day	>10 per day
Patients Esthetic Expectations	Low	Medium	High
Lip Line	Low	Medium	High
Gingival Biotype	Thick	Medium	Thin
Shape of Teeth	Rectangular		Triangular
Infection at Implant Site	None	Chronic	Acute
Bone Level at Adjacent Teeth	<5mm to contact	5.5 – 6.5mm to contact	>7mm to contact
Restorative Status of Neighboring Teeth	Virgin		Restored
Width of Edentulous Span	1 Tooth Ideal	1 Tooth Tight	2 Teeth or More
Soft Tissue Anatomy	Intact Soft Tissue		Soft Tissue Defect
Bone Anatomy at Alveolar Crest	Defect Absent	Horizontal Defect	Vertical Defect

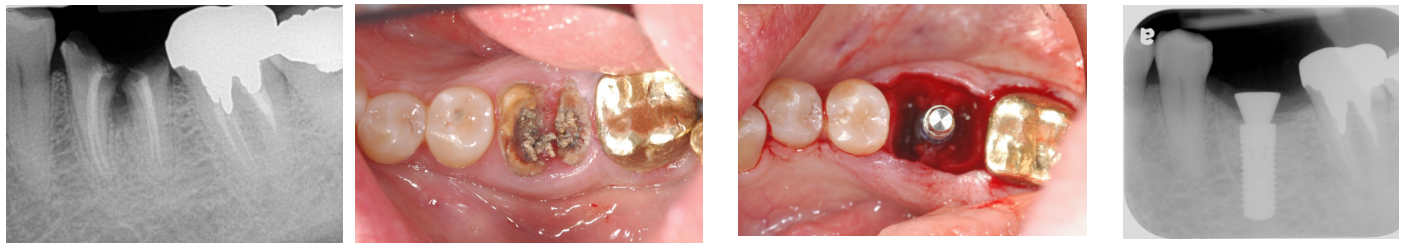\* ITI Treatment Guide, Volume 1: Implant Therapy in the Esthetic Zone. Single Tooth Replacements

**All sites, even for maxillary and mandibular molars, can be immediate implant candidates given the right conditions.**

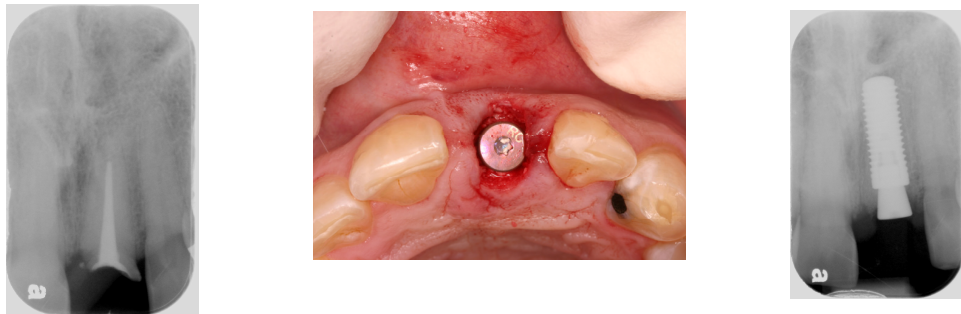
## ***Immediate Implant Cases***



**#4:** Despite close sinus proximity with limited bone beyond the apex, primary stability and ideal restorative position was achieved. The implant width was greater than the width of the ribbon-shaped root of the premolar.



**#19:** Short roots and the presence of interradicular bone with bone beyond the root apices allowed for immediate implant placement because primary stability of the implant was achieved. If the roots are too close together, then immediate implant placement is compromised.



**#9:** Limiting the number of surgeries by completing flapless extraction and implant placement (with assistance from 3-D imaging) was especially important with this site due to highly scalloped tissues and a thin biotype (bone and soft tissue).

**Please call or email if you have questions or comments. We appreciate your feedback and will be happy to discuss in further detail any thoughts or questions you may have.**

**Paul N. Tolmie, DDS**  
paultolmie@charlotteperio.com

**Eric N. Kerr, DDS**  
ekerr@charlotteperio.com

**Kenneth T. Corsig, DMD**  
kcorsig@charlotteperio.com

**Caleb L. Corwin, DDS**  
calebcorwin@charlotteperio.com

**3535 Randolph Road, Suite 103R ♦ Charlotte, NC 28211 ♦ Telephone: 704.365.0123**  
*For more information, please visit our website: [www.charlotteperio.com](http://www.charlotteperio.com)*